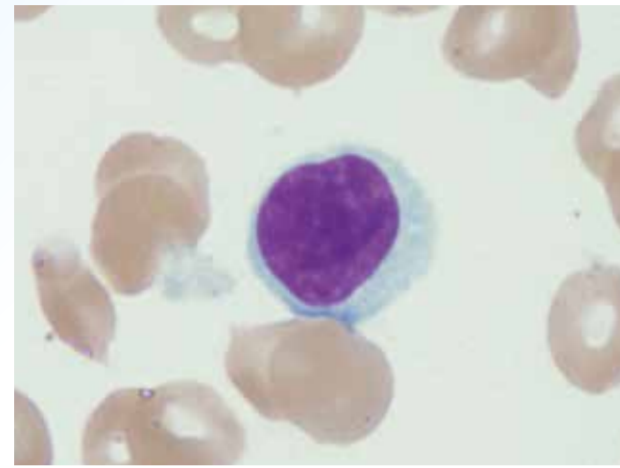


Anormalidades dos linfócitos

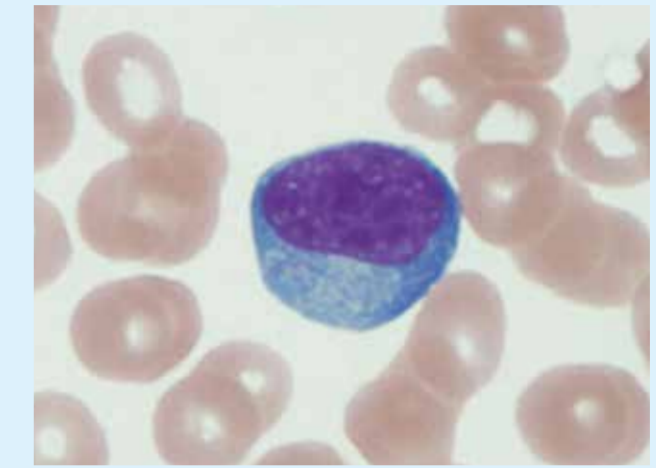
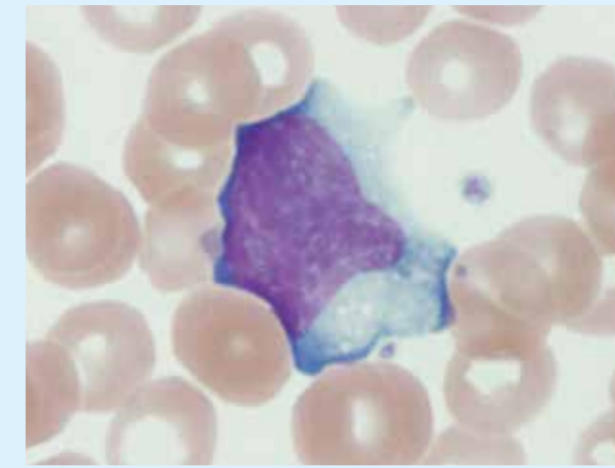
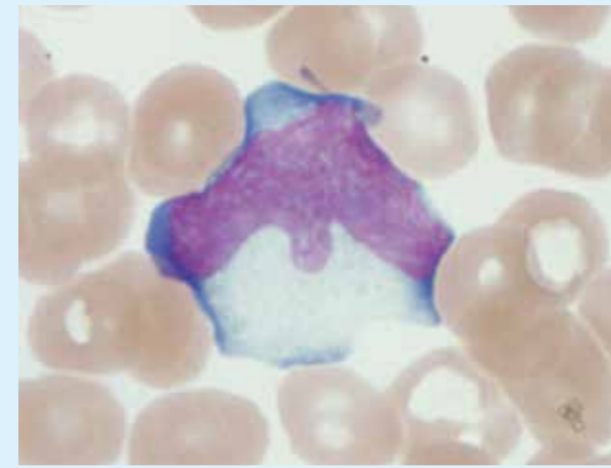
Linfócito normal

正常血液細胞:リンパ球



Linfócitos reativos

反応性リンパ球(異型リンパ球)

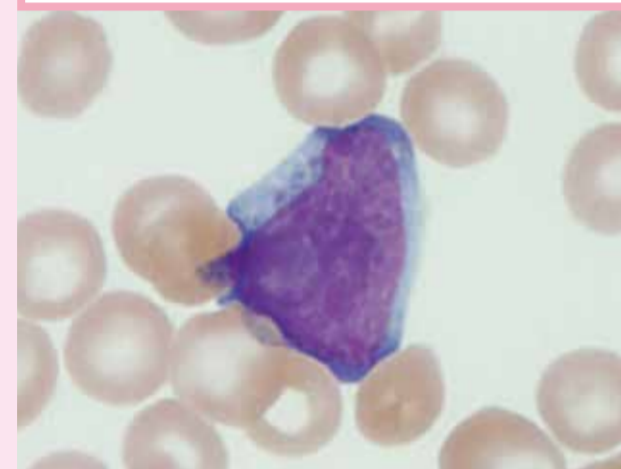


Linfócitos anormais

腫瘍性リンパ球(異常リンパ球)

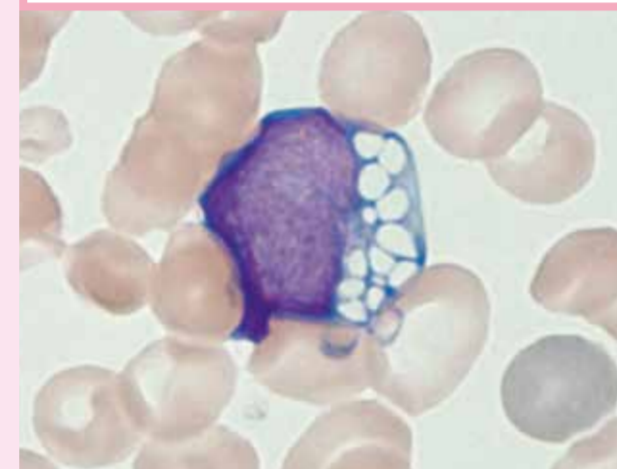
Linfócito anormal em paciente com Linfoma difuso de grandes células B

びまん性大細胞型B細胞リンパ腫



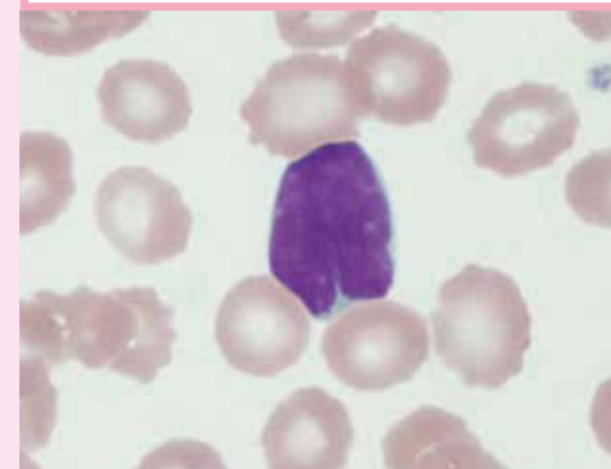
Linfócito anormal em paciente com Linfoma de Burkitt

バーキットリンパ腫



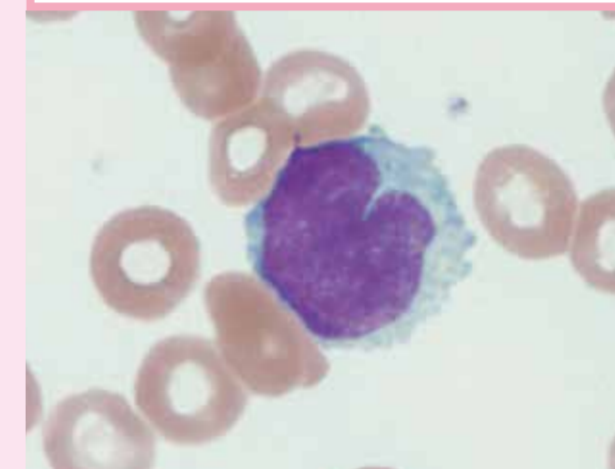
Linfócito anormal em paciente com Linfoma folicular

濾胞性リンパ腫



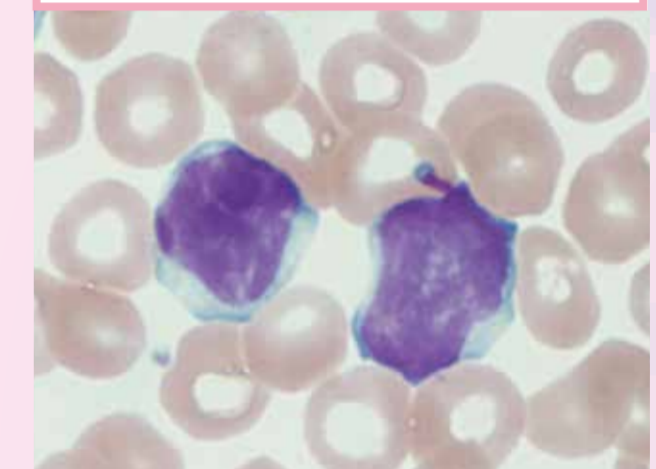
Linfócito anormal em paciente com Linfoma de células do manto

マンデル細胞リンパ腫



Linfócitos anormais em paciente com Leucemia linfocítica crônica

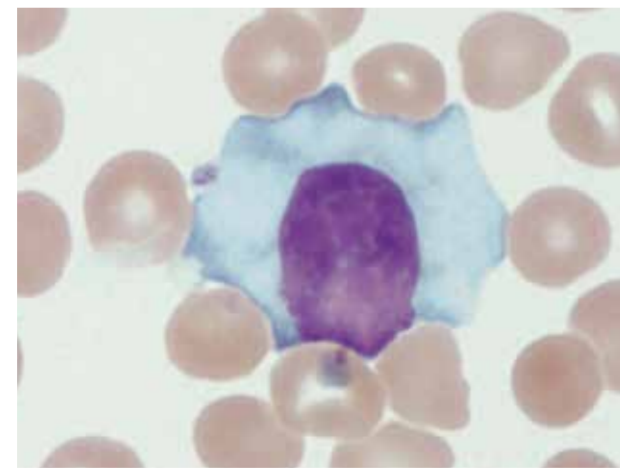
慢性リンパ球性白血病



Célula pilosa em paciente com leucemia de células pilosas

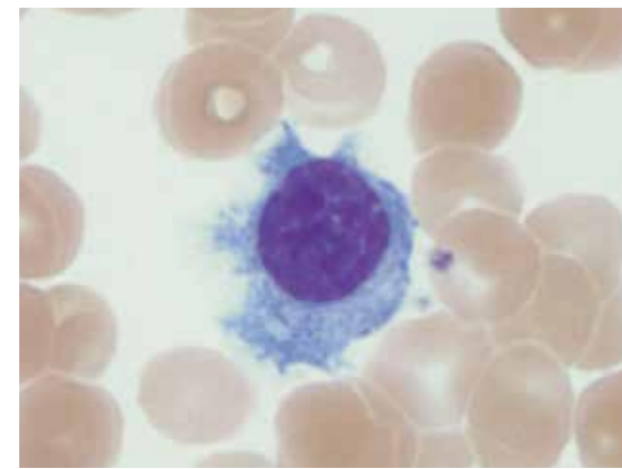
Por secagem forçada

有毛細胞白血病(冷風強制乾燥)



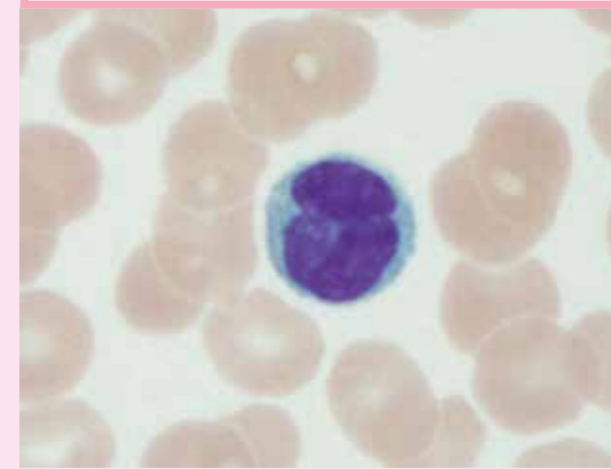
Por secagem natural

有毛細胞白血病(自然乾燥)



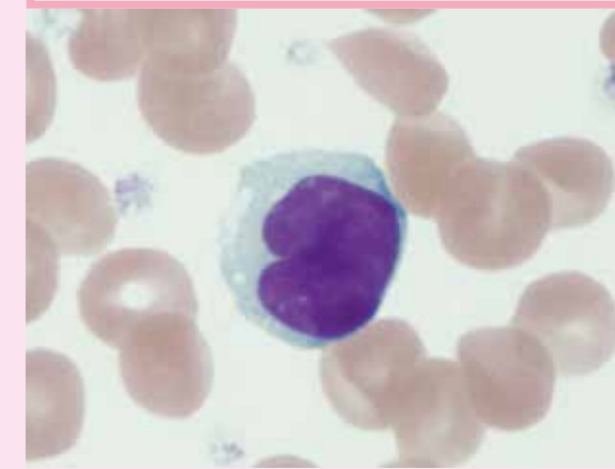
Linfócitos anormais em paciente com Leucemia de células T do adulto

成人T細胞白血病



Células de Sézary em paciente com Síndrome de Sézary

セザリー症候群



Linfócito granular grande em um paciente com leucemia linfocítica de células T granulares grandes

T細胞大型顆粒リンパ球性白血病

