

Hematopoiese

Médula Óssea

Sangue Periférico

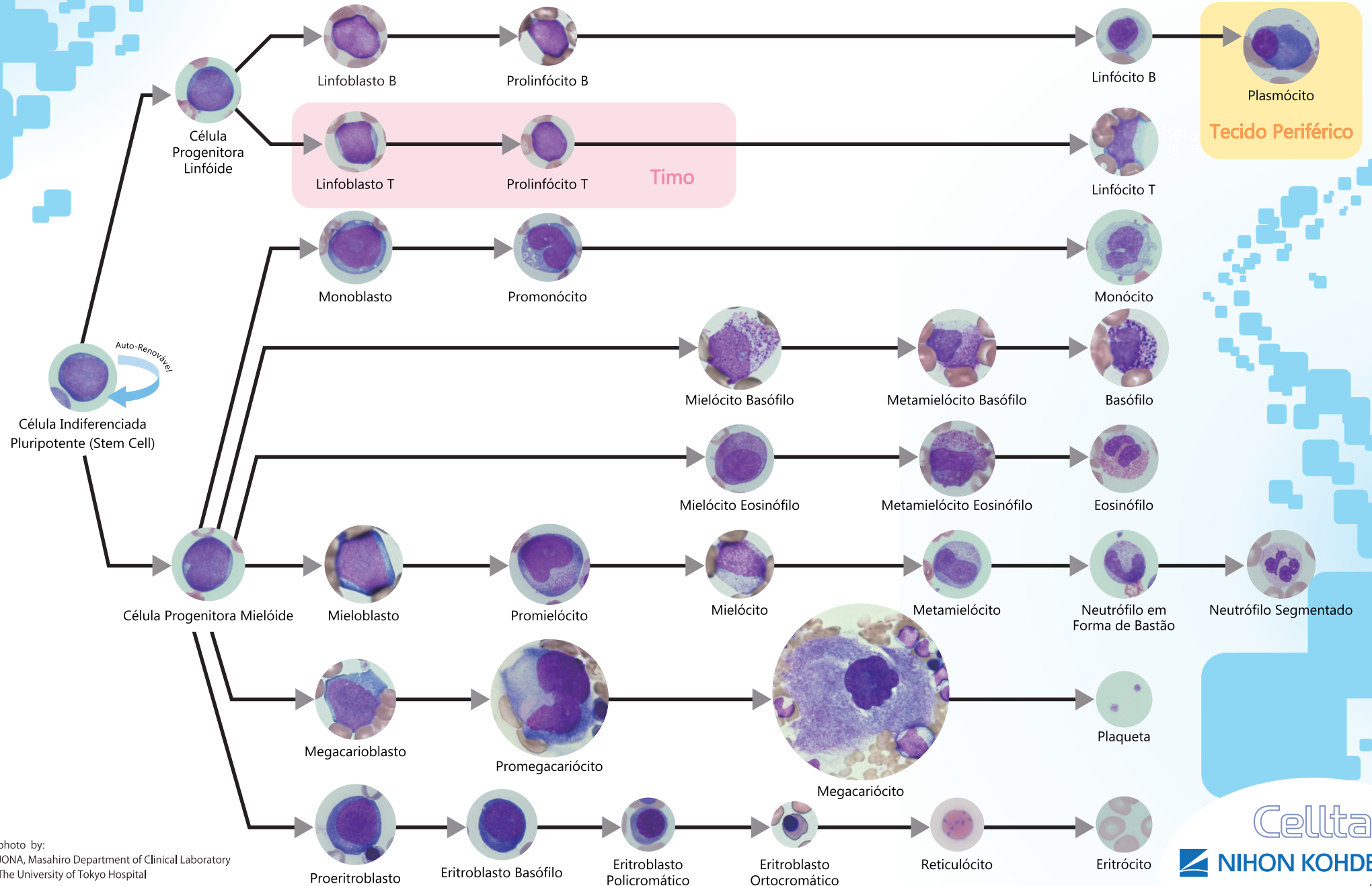


photo by:
JONA, Masahiro Department of Clinical Laboratory
The University of Tokyo Hospital